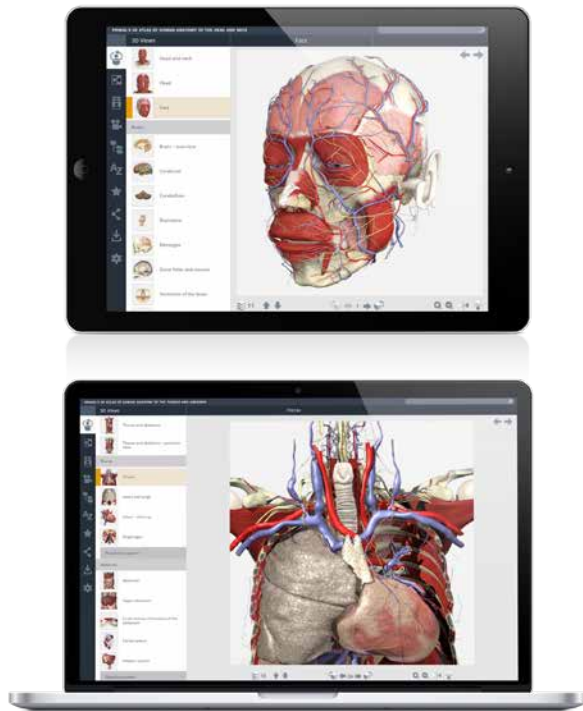
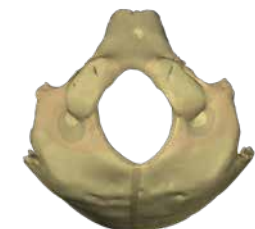
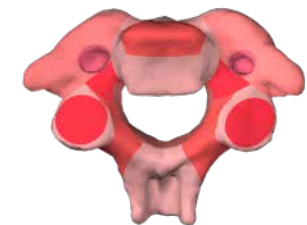
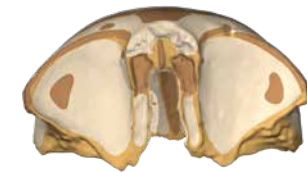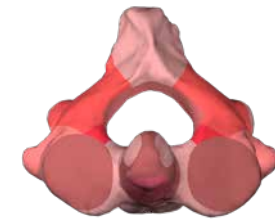


Primal's 3D Atlas and 3D Human on Anatomy.tv

Welcome to our user guide to **3D Atlas** and **3D Human** on Anatomy.tv. Please read on, or select one of the links opposite to jump straight to a particular topic.



Anatomy.tv –	
Getting started	2
Logging in	3
Landing page	4
Further help	5
Main interface –	
Overview	6
Opening and closing panels	7
Finding content –	
3D views tab	8
Search panel	9
Identifying structures –	
Visible structures list	10
Rollover labels	11
Interacting with the 3D model –	
Selecting structures	12
Sequences	13
Layers	14
Zoom and Flip	15
Main tabs –	
Imaging	16
Slides	17
Movies	19
Anatomical structures	20
Index	21
Favorites	22
Share	23
Save	24
Settings	25
Specialist tabs –	
Animations	26
Clinical	27
Patient information	28



RECOMMENDED BROWSERS

For an optimum experience we recommend using one of the following web browsers:



Chrome



Microsoft Edge



Internet Explorer



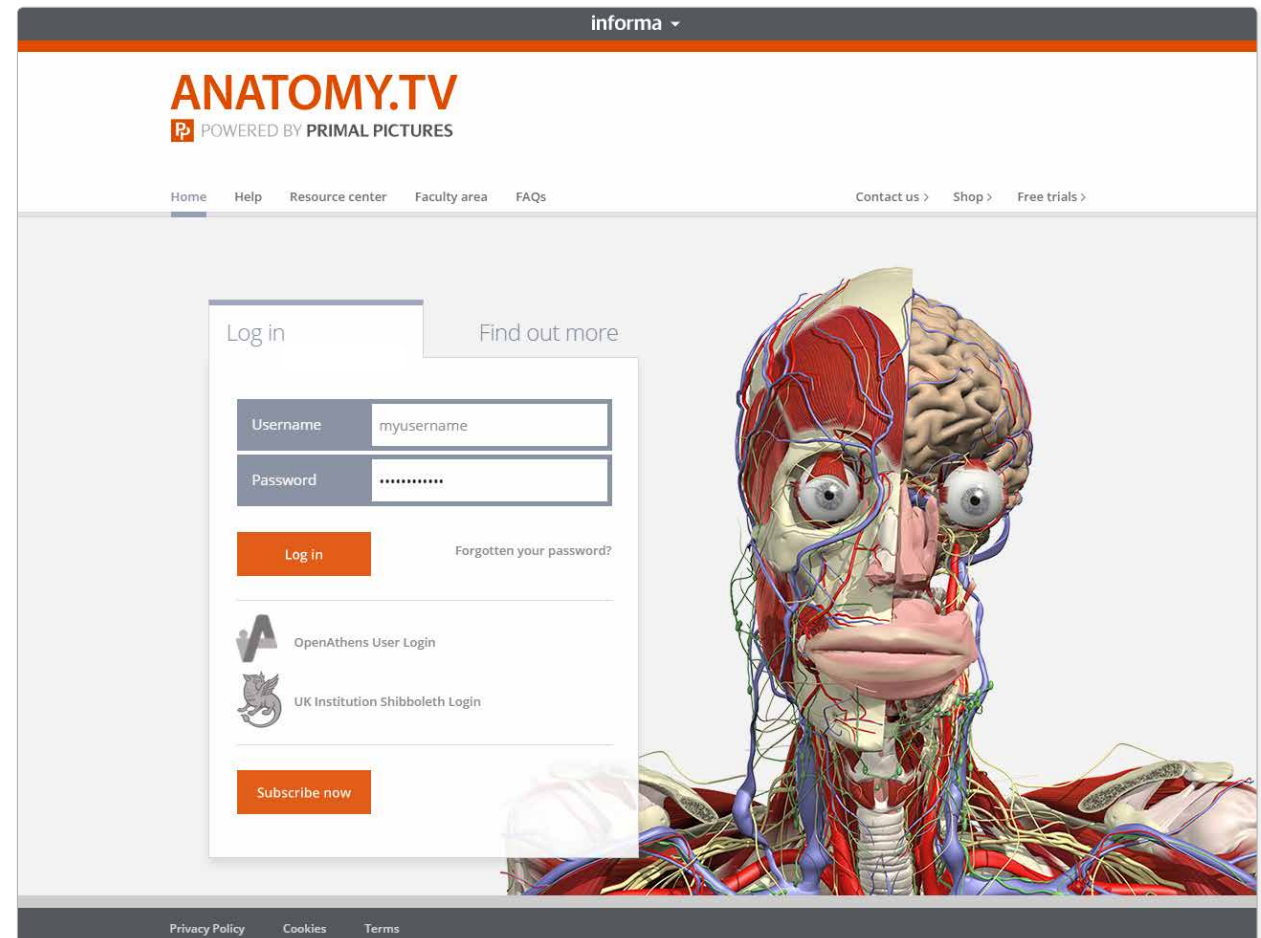
Mozilla Firefox



Safari

Open your web browser and type www.anatomy.tv into your address bar or browser search field.

This takes you to the home page:



Please type your username and password in the subscriber login fields.

Main navigation

The top navigation bar offers a number of useful links – you may find the Help link, which takes you to our in-depth reference and video tutorials pages, particularly useful.

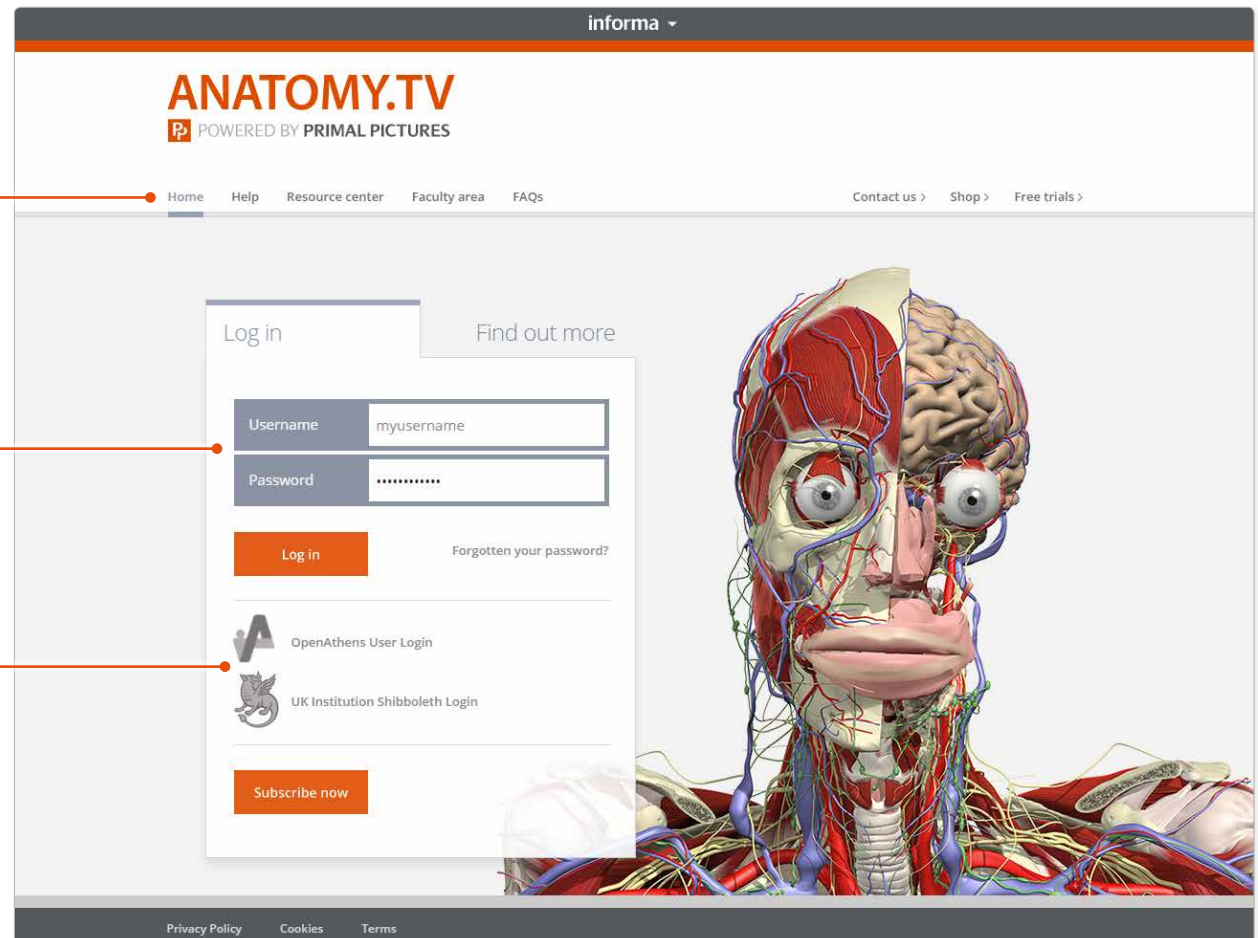
The Resource centre links to a stock of Anatomy.tv and Primal Pictures information and publicity resources.

Username and Password

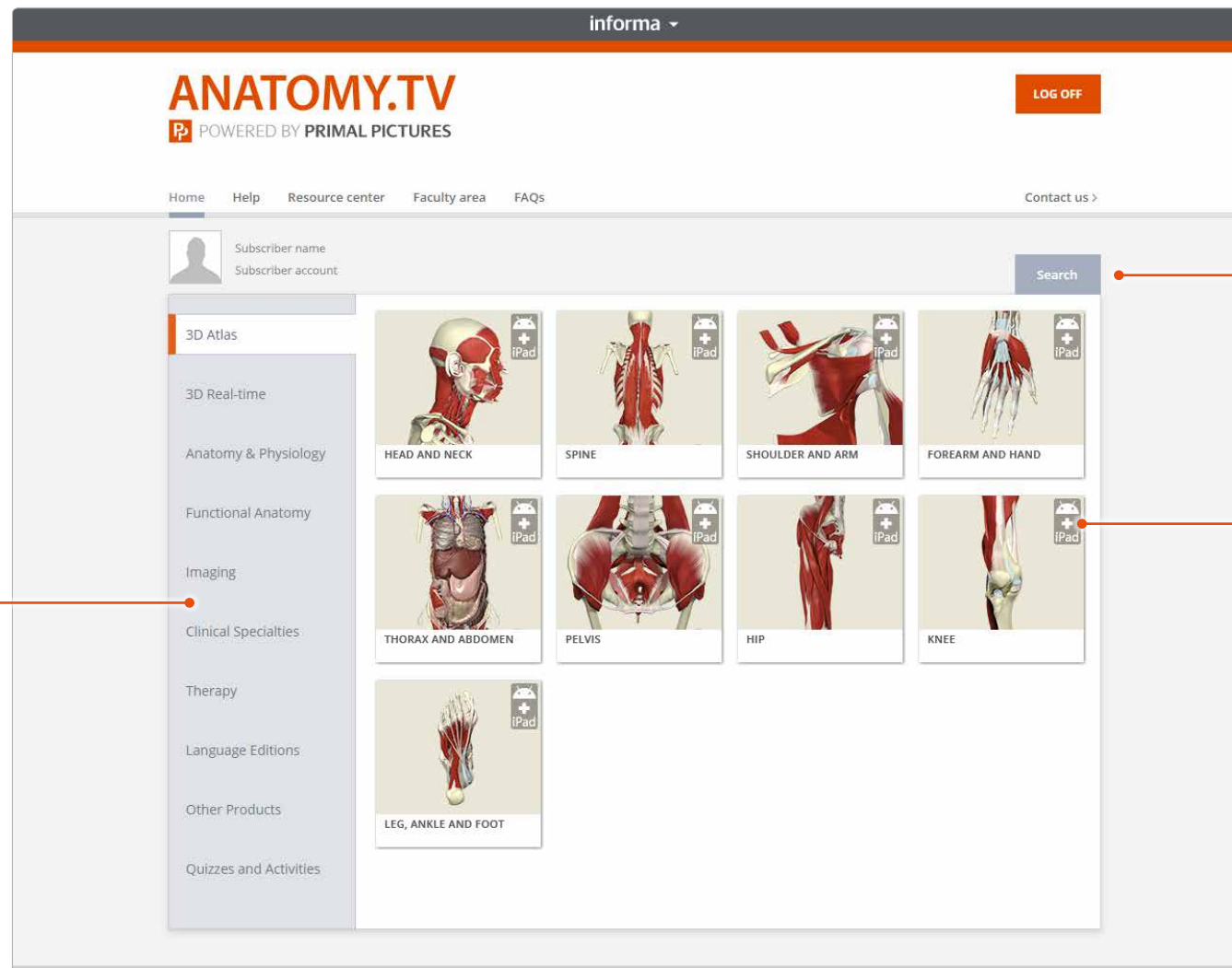
Note that if your institution is IP authenticated you will be taken to the products page automatically without having to log in so you will not see this page and login area.

Other portals

Athens or Shibboleth users should click on the appropriate link and log in via the Athens or Sibboleth sites.



Once you have entered a valid username and password you'll be taken to the product launch area of the Home page.



Our titles are split into categories which can be accessed on the left-hand-side tab menu.

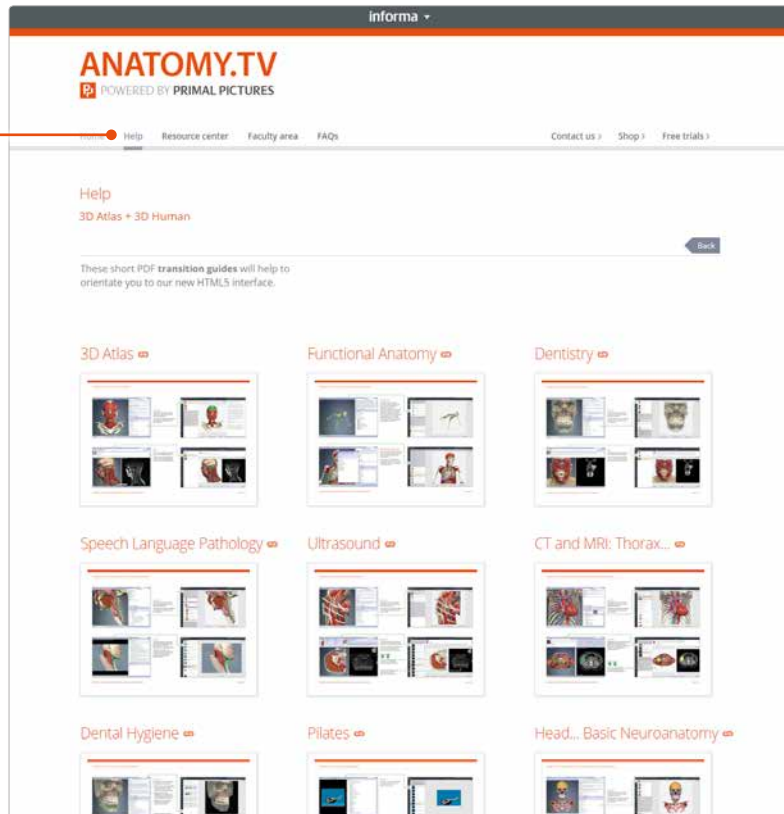
You can search for content throughout your subscription here.

Products which are accessible via tablet devices are indicated by this icon.

You can find other types of learning materials on the Help pages of Anatomy.tv. These resources can also be accessed via the [Help and About](#) panel.

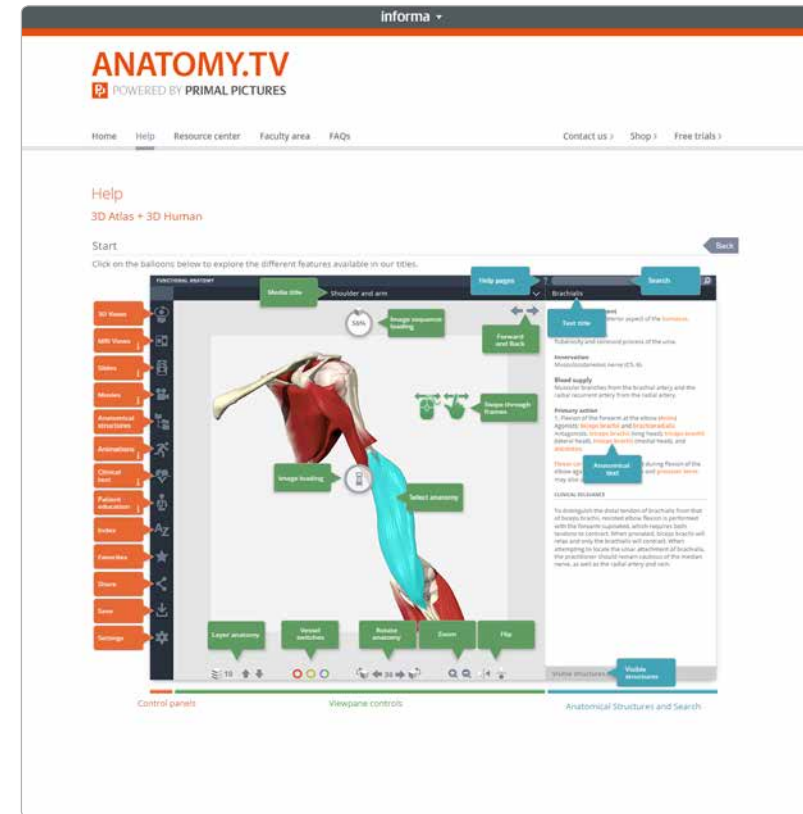Transition guides

If you are used to our old user interface, these PDF documents will help orientate you to the new one.



Point-and-click

This type of help is useful if there is a particular button, icon or user-interface feature you would like to learn about.



Main interface – Overview



The interface consists of three main areas:

Browse panel

Use this panel to navigate through the content. The buttons down the left-hand-side allow you to access this content by media type, structure type or alphabetically.

The lower buttons allow you to share, save content, as well as adjust the settings.

1

View panel

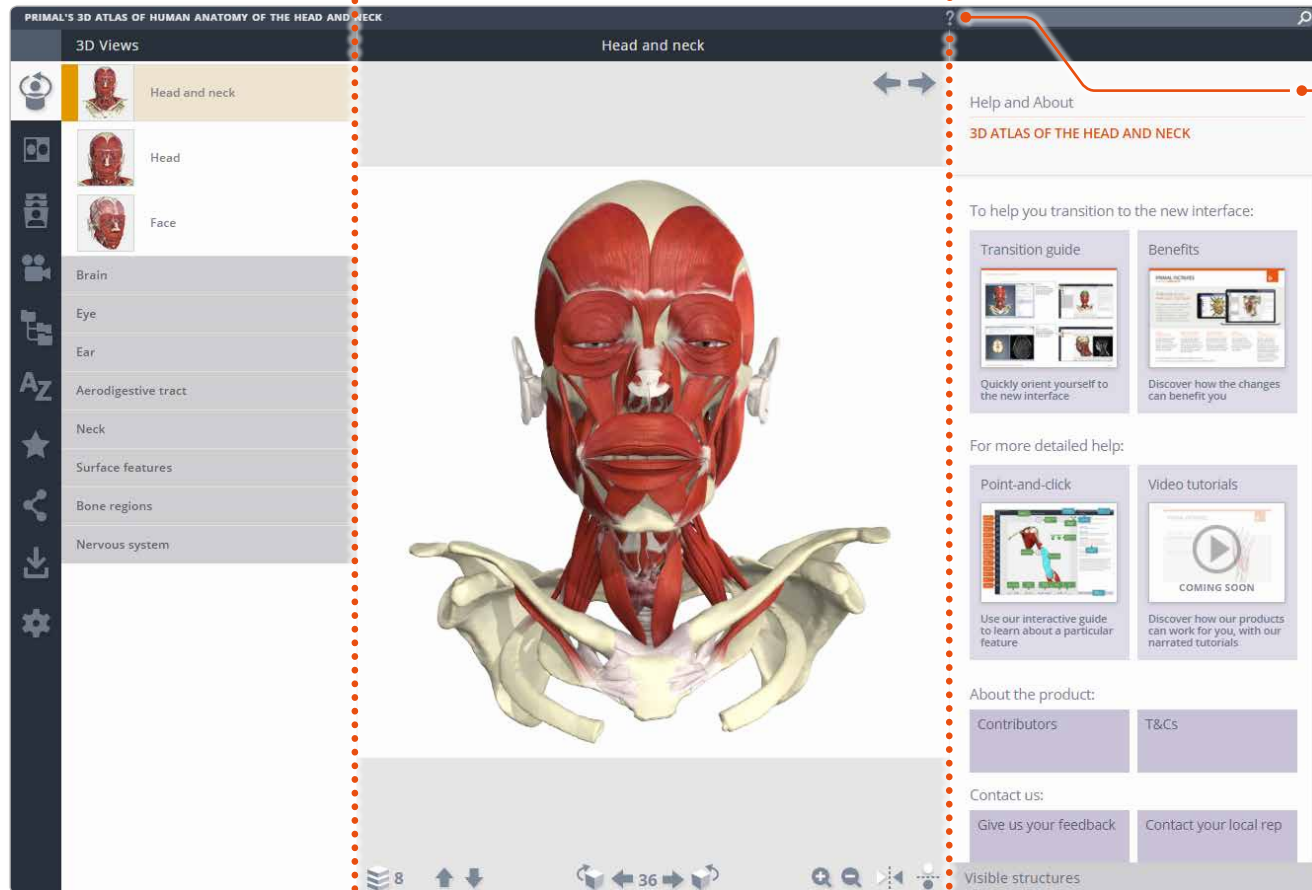
This area is where you can view and interact with content.

2

Text panel

This panel is where you can read about structures you've selected in the **View panel**. You can also search for content, as well as selecting from the list of **Visible structures**.

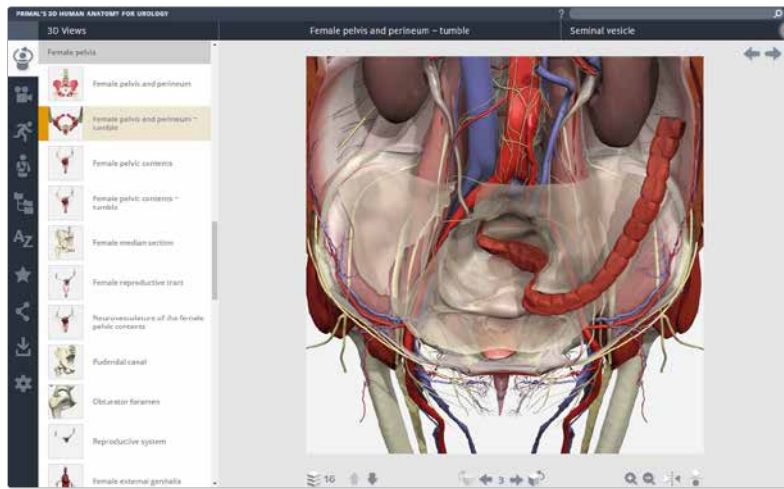
When you first launch the product, the **Text panel** contains the **Help and About** section, which can be accessed at any time by clicking on the Help icon.



Main interface – Opening and closing panels

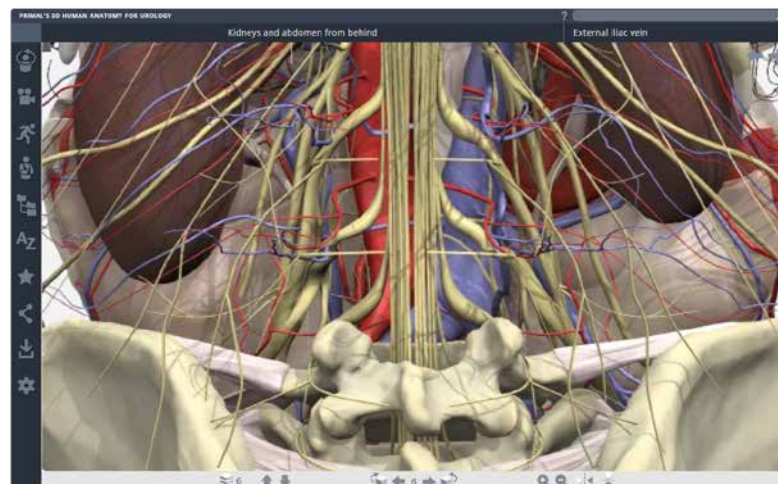
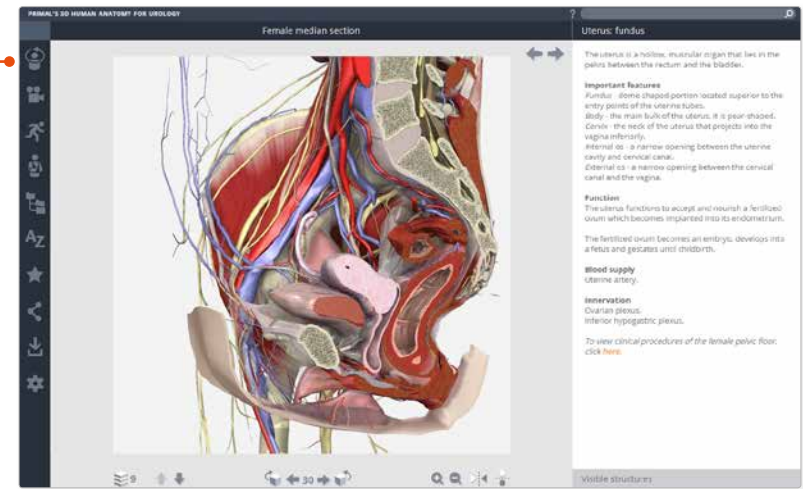


You can arrange the workspace to suit your needs.
This can be especially useful on smaller screens or tablet devices.



To open or close the **Text panel**,
click on the header.

To close the **Browse panel**,
click on the active menu tab.



For even more focus, both
panels can be closed.

In this example, the view has been
enlarged using the **Zoom controls**.

Finding content – 3D views tab



There are several ways to locate anatomical structures.
Firstly, you can browse the **3D views** in the Browse panel.

In the 3D views tab, simply click on a folder to open it,
then select one of the 3D views contained within for it to
be displayed in the View panel.

The screenshot displays the 'PRIMAL'S 3D ATLAS OF HUMAN ANATOMY OF THE HEAD AND NECK' interface. On the left, the '3D Views' tab is active, showing a hierarchical list of anatomical folders. The 'Tongue' folder is selected and highlighted in orange. The main 'View' panel shows a 3D anatomical model of the tongue and surrounding structures, with the 'Superior longitudinal muscle' highlighted in green. To the right of the model, a text panel provides details about the muscle, including its description, nerve supply (hypoglossal nerve), and action. Three numbered annotations are present: '1' points to the folder structure, '2' points to the 'Tongue' folder, and '3' points to the view name 'Tongue' in the top bar. A double-headed arrow icon is also shown above the model, indicating navigation controls.

3D VIEWS TAB

1 The content is arranged into folders. Simply click on a folder to open it.

2 Each 3D view has a thumbnail preview. Click on the thumbnail (or the title next to it) to load that view into the View panel.

3 The name of the view appears here.

Use these buttons to move backwards and forwards through your viewing history.

PRIMAL'S 3D ATLAS OF HUMAN ANATOMY OF THE HEAD AND NECK

3D Views

Face

Brain

Eye

Ear

Aerodigestive tract

Oronasal cavities

Oronasal cavities ~ neurovasculature

Larynx

Pharynx / larynx

Nose and nasal cavity

Oral cavity

Oral cavity

Tongue

Palate ~ from below

Floor of oral cavity ~ from above

Tongue

Superior longitudinal muscle

This intrinsic muscle of the tongue is a thin strip of oblique and longitudinal fibers. It can be found lying underneath the dorsal lingual mucosa. The muscle extends forwards from the median lingual septum and from the submucous fibrous tissue near the epiglottis to the lingual margin.

Nerve supply
The muscle is supplied by the **hypoglossal nerve**.

Action
The superior longitudinal muscle alters the shape of the tongue by shortening it, with the inferior longitudinal muscle, and turning the apex and sides upwards to make the dorsum of the tongue concave. Alone, pairs or in conjunction with the other intrinsic muscles of the tongue, the tongue is able to follow precise and varied mobility, used in speech and mastication.

Visible structures

Finding content – Search panel



If you know the name, or part of the name, of a structure you can locate it using the **Search** feature.

1 | Begin typing your search term here – the Search panel will appear over the top of the Text or View panel below.

2 | The search results will appear below, sorted into folders. (You can uncheck the filters above if you are looking for only a certain type of content.)

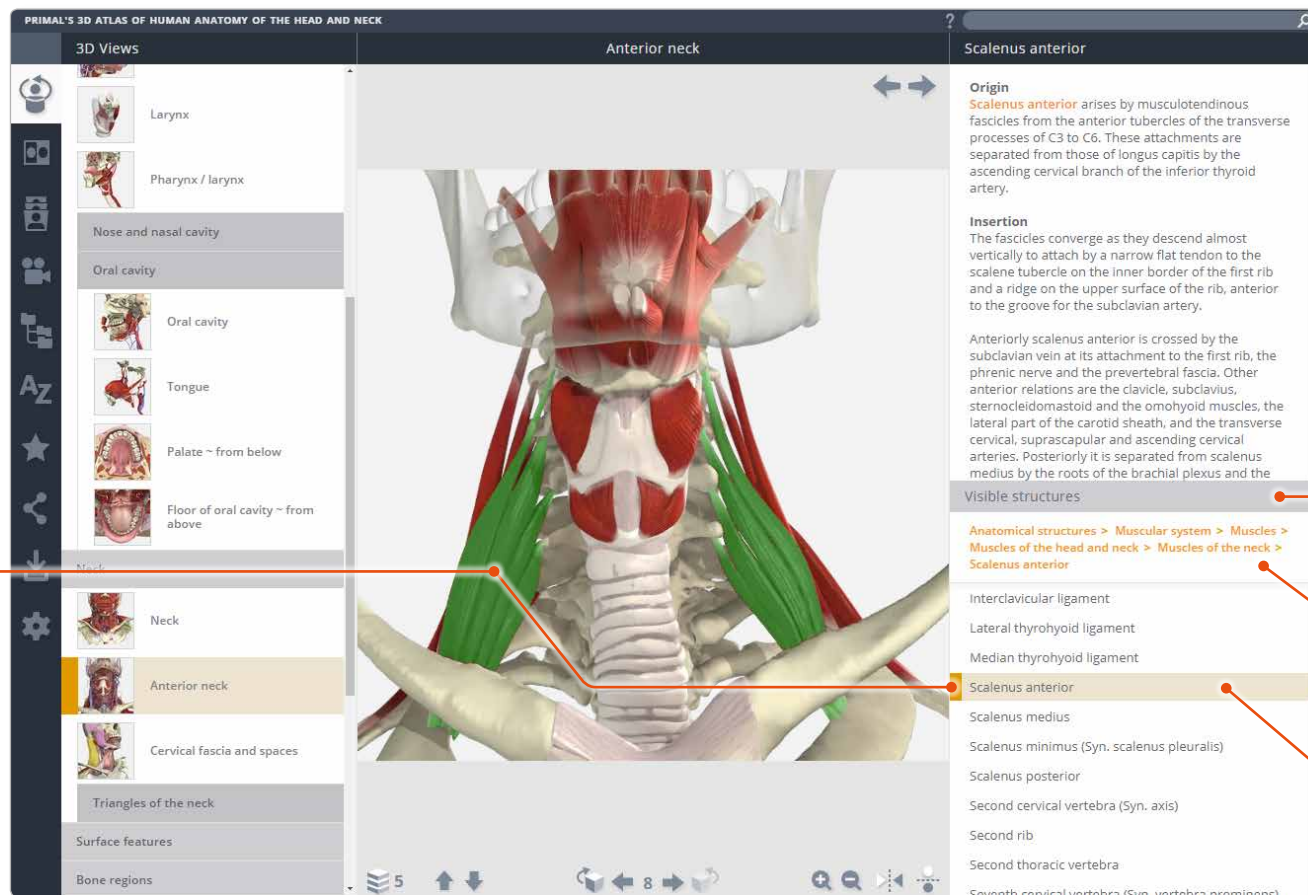
3 | Open a folder and click on the desired result to load it into the View panel.

4 | Once you have completed your search, close the Search panel by clicking on the cross.

Identifying structures – Visible structures list



Visible structures lists only those structures included in the current view. You can select a structure name from the list to highlight that structure in the View panel.



3

Alternatively, you can select a structure in the View panel and its name will be highlighted in the Visible structures list.

VISIBLE STRUCTURES

2

The 'cookie-crum trail' shows the structure's location in the anatomical hierarchy.

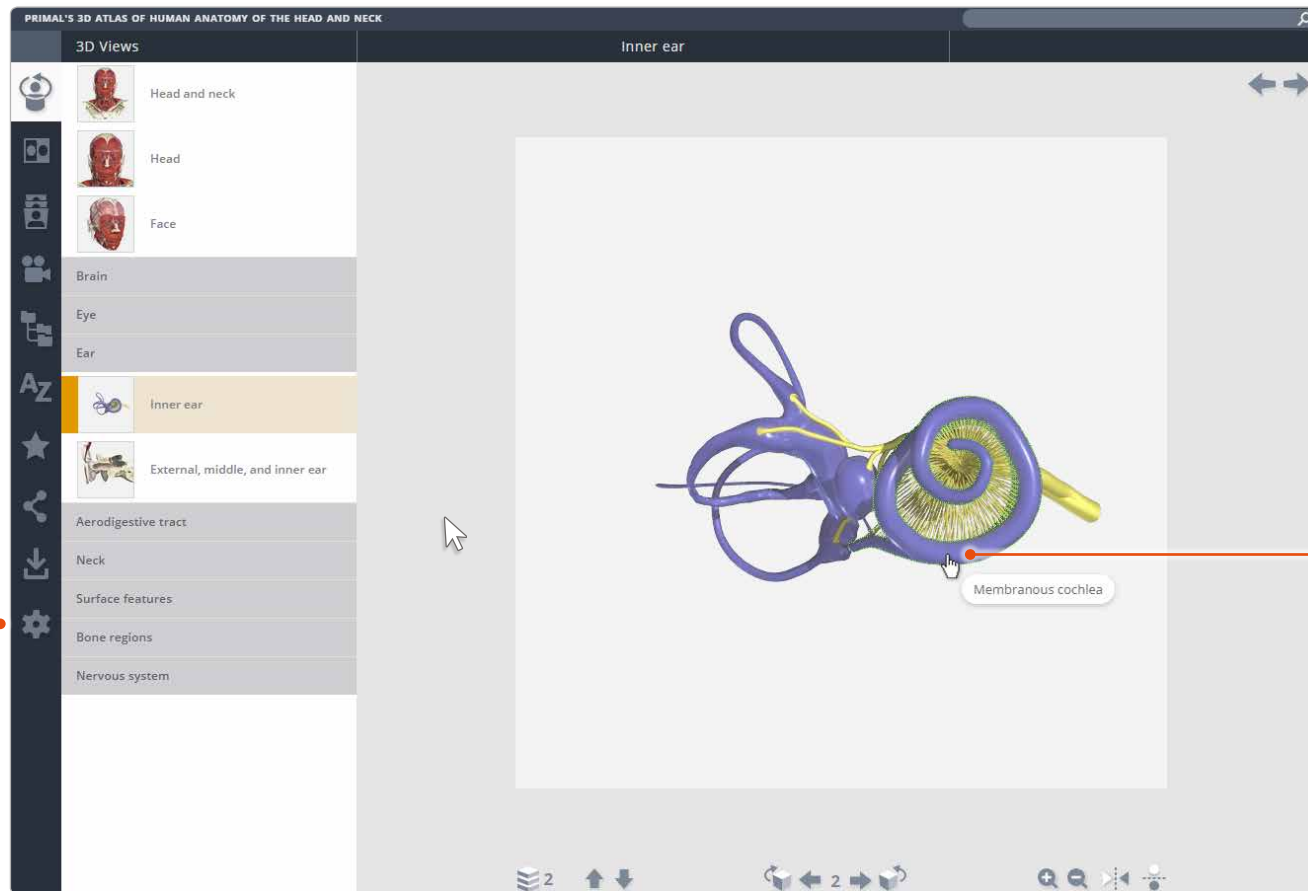
1

Select a structure name to highlight it in the View panel.

Identifying structures – Rollover labels



All selectable 2D and 3D images feature **rollover labels** to help you identify structures.



2

You can turn off the rollover labels in Settings. For example, you may wish to test yourself on the names of structures in the View panel.

1

Hovering over a structure with your mouse pointer will reveal the structure's name.

Interacting with the 3D model – Selecting structures



Every structure in a 3D view is selectable – simply click on a structure and it will highlight.

1 Here, the Procerus has been clicked on.

2 The name of the highlighted structure appears here, followed by detailed anatomical text.

3 Most texts include links to related content.

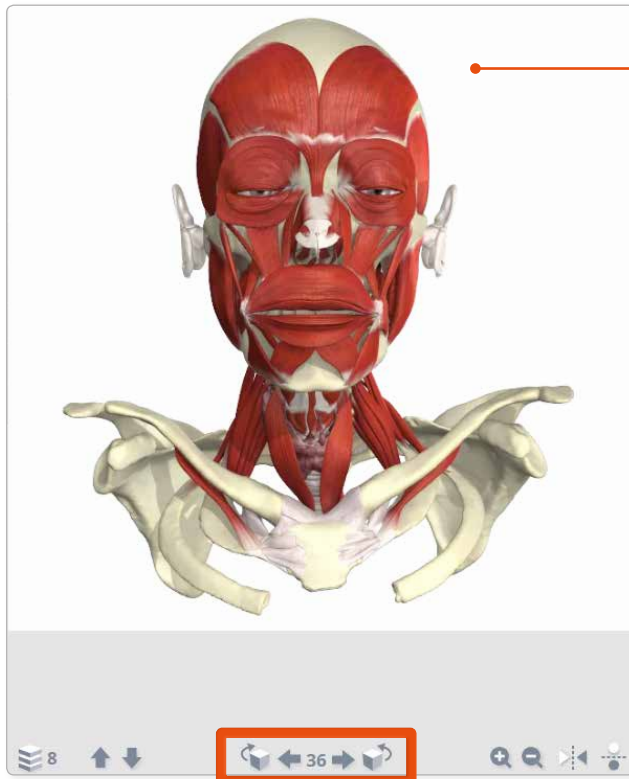
4 You can deselect structures by clicking on the background.

The screenshot shows a 3D anatomical model of the human head and neck. The Procerus muscle is highlighted in green. The interface includes a sidebar on the right with a search bar and a list of details for the selected structure. The details include Origin, Insertion, Nerve supply, Vasculature, Action, and Pathology. The sidebar also has a search icon and a close icon. The main view shows the 3D model with a toolbar on the left and a bottom toolbar with navigation and zoom controls.

Interacting with the 3D model – Sequences

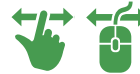

Every 3D view is made up of a sequence of images. These sequences usually take the form of rotations, enabling you to study the anatomy through 360 degrees.

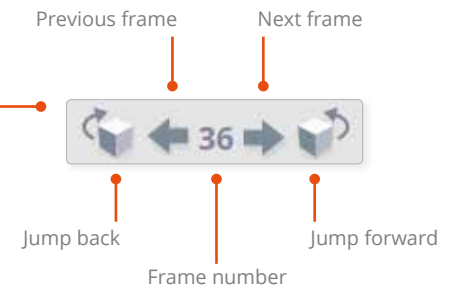


Frame controls

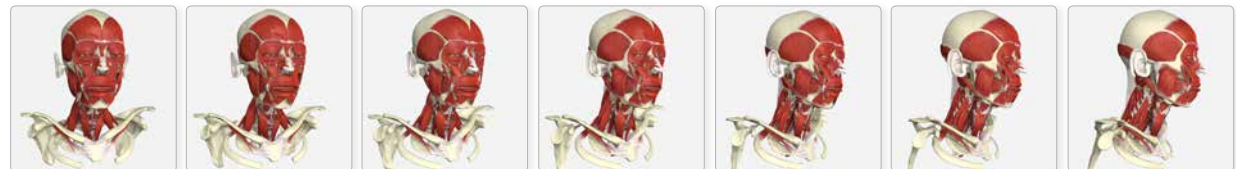
Drag with your mouse or finger in the image area of the View panel to move through the frame sequence.



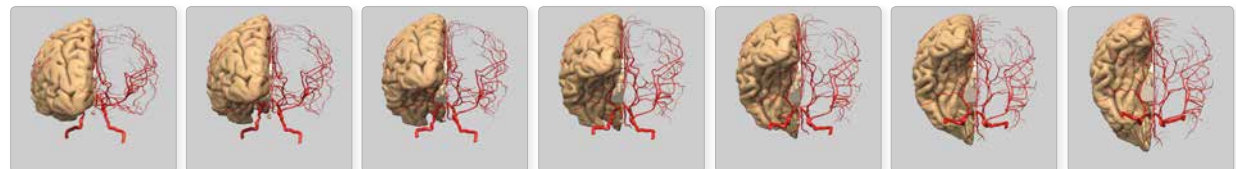
For finer control, use the Frame controls at the bottom of the View panel.



PART OF A HORIZONTAL ROTATION SEQUENCE



SOME SEQUENCES ALSO SHOW VERTICAL ROTATIONS



Interacting with the 3D model – Layers

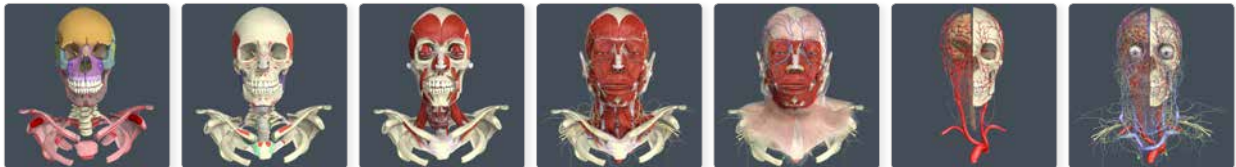

All 3D views also feature numerous **layers**. Use the control buttons on the bottom toolbar to navigate through them.

Use the **Choose layer** button to jump rapidly through the layers. Up layer Down layer

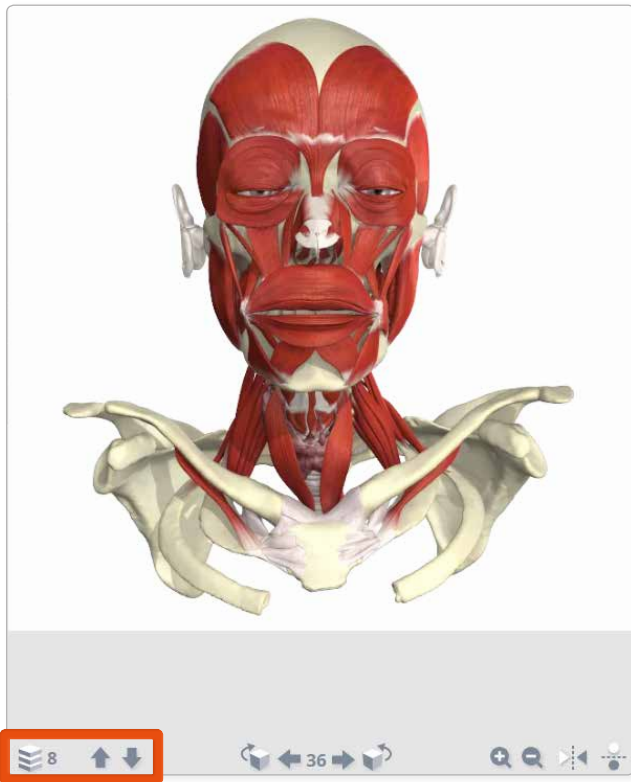


EXAMPLES OF HEAD AND NECK LAYERS

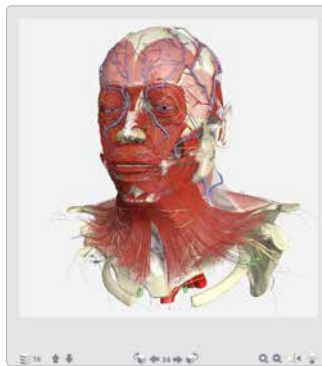


Note that when you choose a different 3D view, your layer and frame selection will remain the same in the new view...

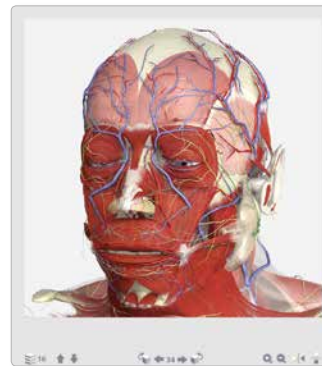
... however, if the new view doesn't have that particular layer (or frame), it will be reset to 1.



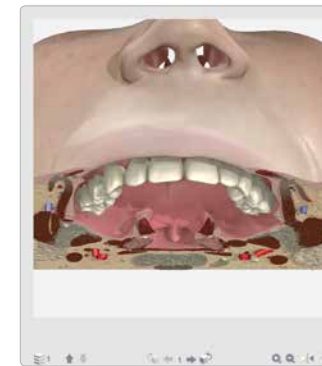
Layer controls



HEAD AND NECK



HEAD



PALATE ~ FROM BELOW

Interacting with the 3D model – Zoom and Flip

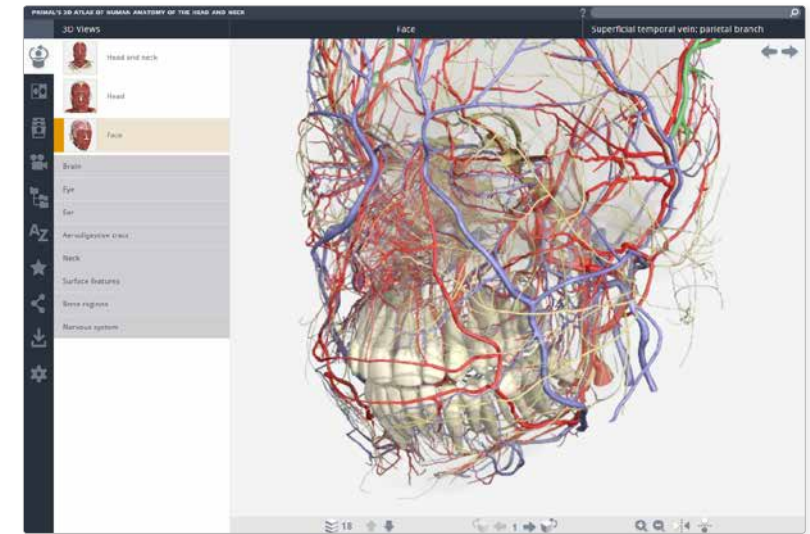
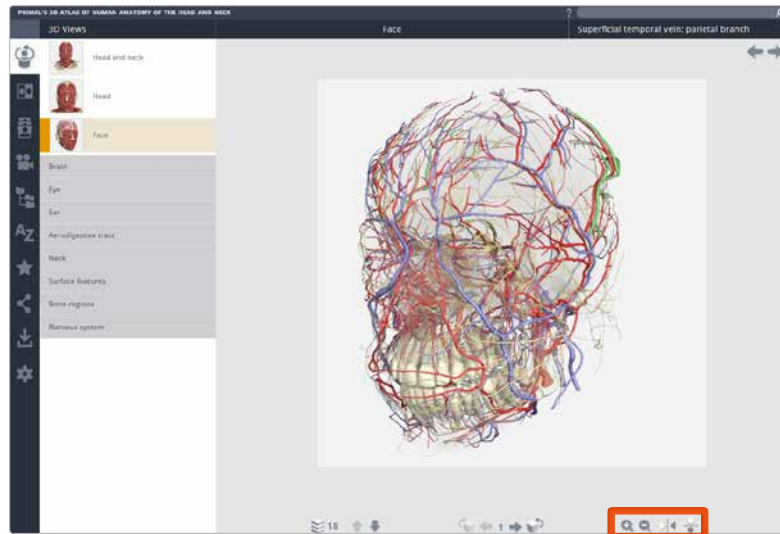


The **Zoom** controls allow a closer look at the model.

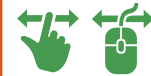Note that the image will become less sharp as you zoom in. As an alternative to using zoom, you may well be able to find a closer view of the structure you are interested in using the **3D views** tab or by using the **Search** feature.



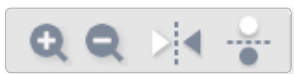Zoom in Zoom out



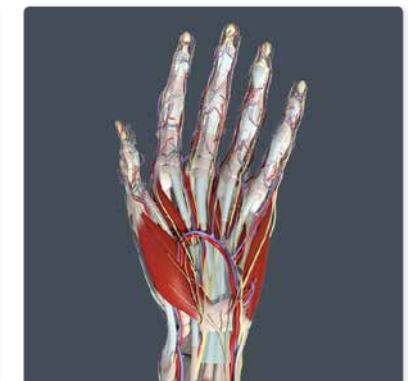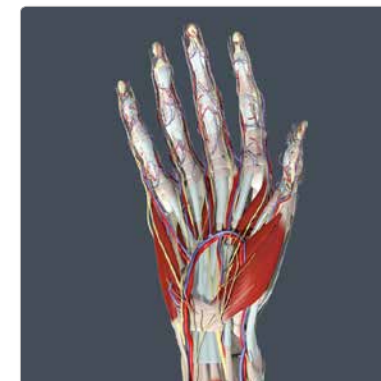
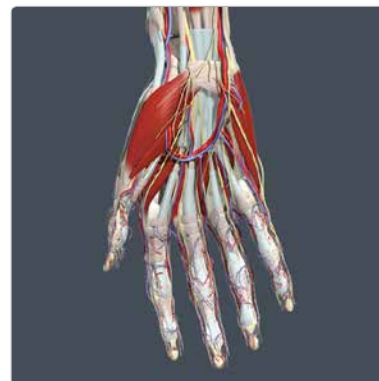
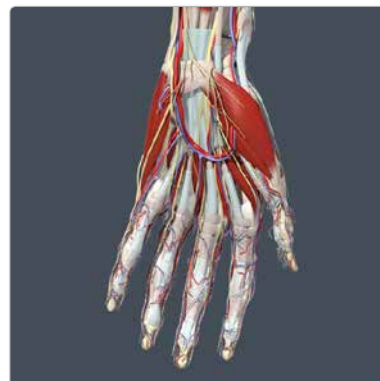
While zoomed in, dragging with the mouse or finger will move rather than rotate the image. If you wish to rotate the image while zoomed, use the **Frame controls**



The **Flip** controls are useful when you want to show the opposite side of the body, or change the view's vertical orientation.



Flip horizontally Flip vertically



Main tabs – Imaging



The **Imaging*** tab features side-by-side viewing panes, enabling you to compare our 3D model with equivalent scans.

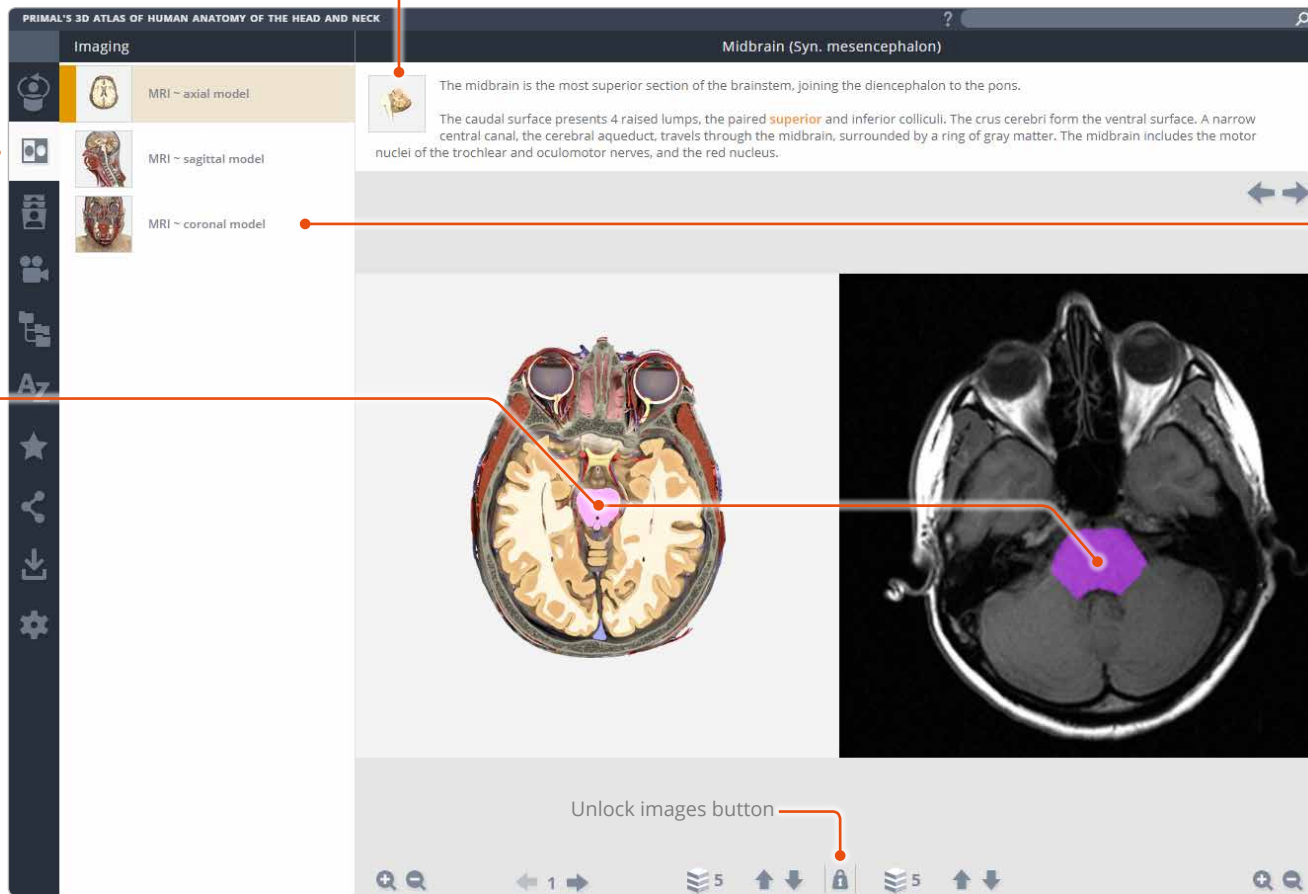
Clicking on the **Best view** thumbnail will open that view in the View panel.

IMAGING TAB

Structures selected in one pane will highlight in the other (if visible in both panes).

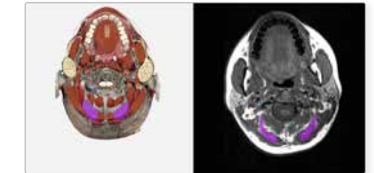
Note that the Imaging slides are taken from a different specimen to our 3D model – therefore, due to anatomical differences, the two views will not match completely.

Use the **Change plane position** buttons to move through the slices. By default they control both panes simultaneously. However, you can unlink them by toggling the **Unlock images**** button – useful if you cannot see a particular structure in both panes.

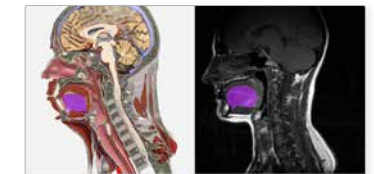


Choose whether to view the Axial, Sagittal or Coronal plane by selecting the thumbnails in the Browse panel.

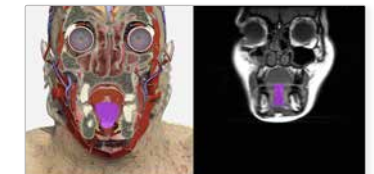AXIAL PLANE



SAGITTAL PLANE



CORONAL PLANE



* The Imaging tab features in the 3D Atlas titles; Ultrasound titles; CT and MRI: Thorax, Pelvis and Abdomen; Otolaryngology; Chiropractic; Dentistry; Neuroanatomy.

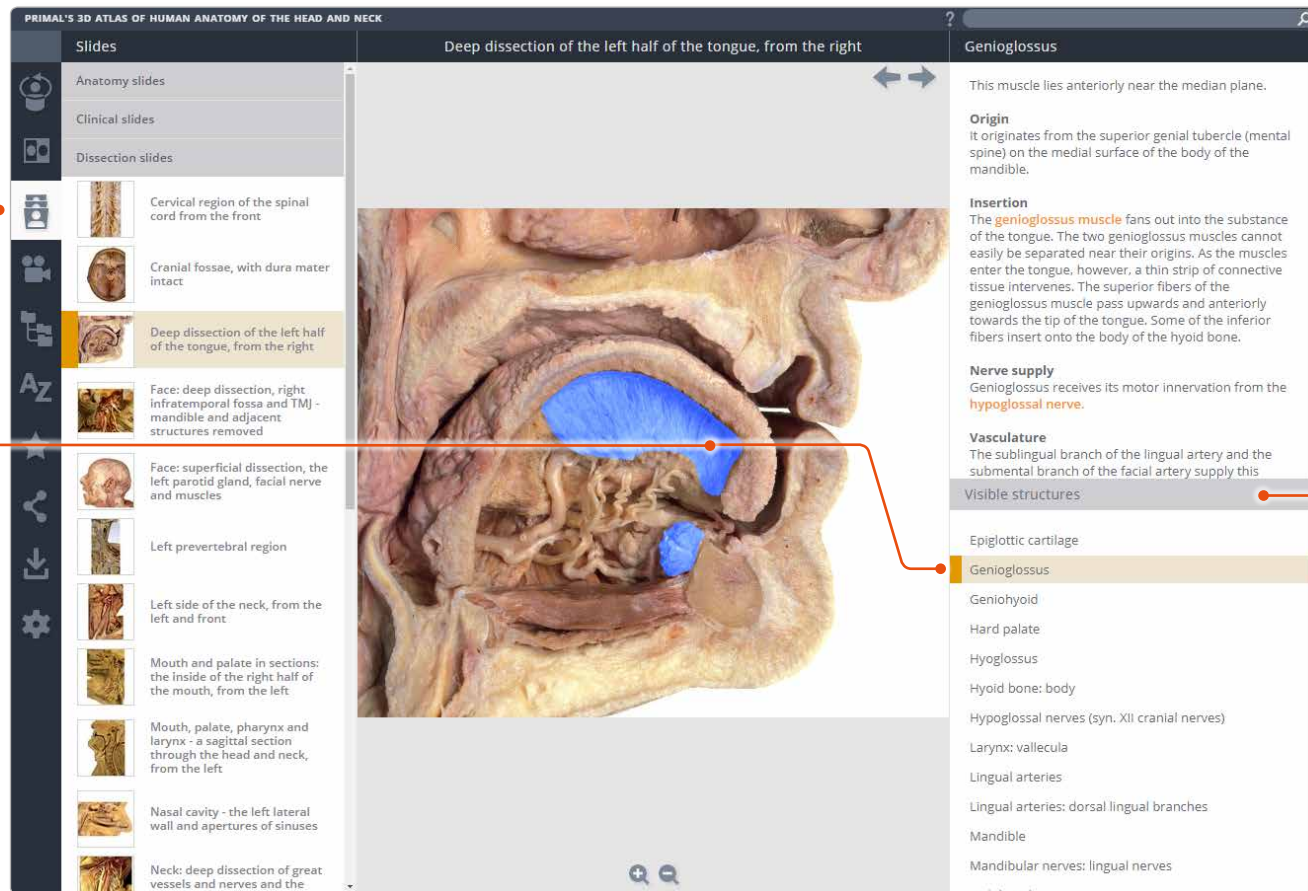
** The Unlock images button does not appear in Ultrasound titles.

Main tabs – Slides



The **Slides tab*** contains clinical photographs, scans and diagrams, many of which feature selectable structures.

(See the next page for the types of content that are included.)



SLIDES TAB

2

Structures may be selected in the View pane, or chosen from the Visible structures list.

1

If a slide has selectable structures, the **Visible structures** bar will be shown at the bottom of the Text panel. Clicking on it expands the box, revealing the list.

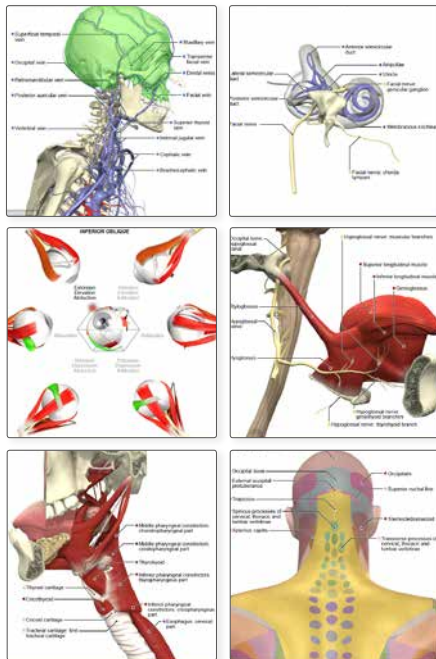
* Slides do not feature in Yoga; Resistance Training; Urology; Anatomy Trains.

Main tabs – Slides (continued)

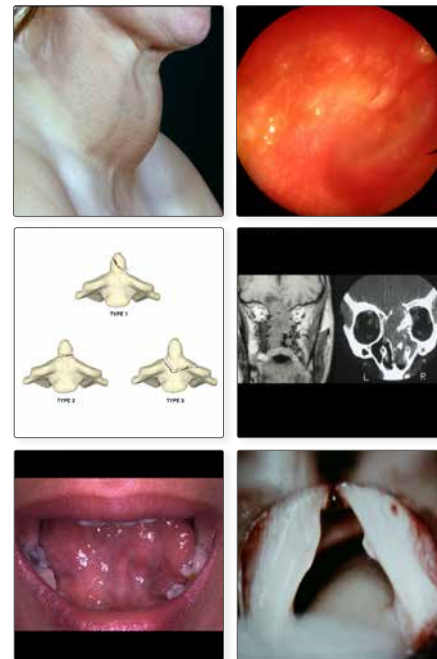


The **Slides** content is divided into four types.

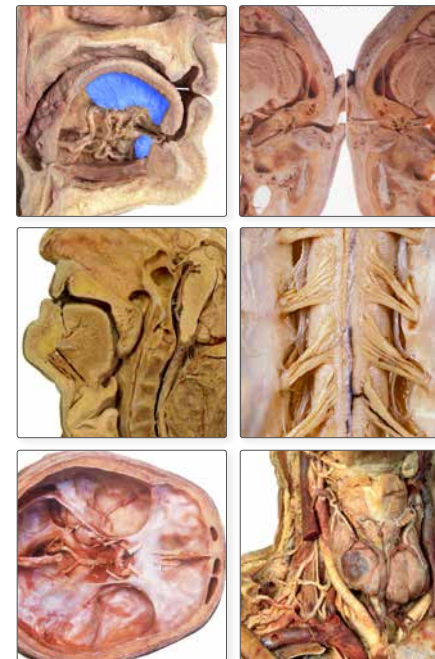
Anatomy slides are annotated diagrams or photographs, showing selected areas of anatomical interest.



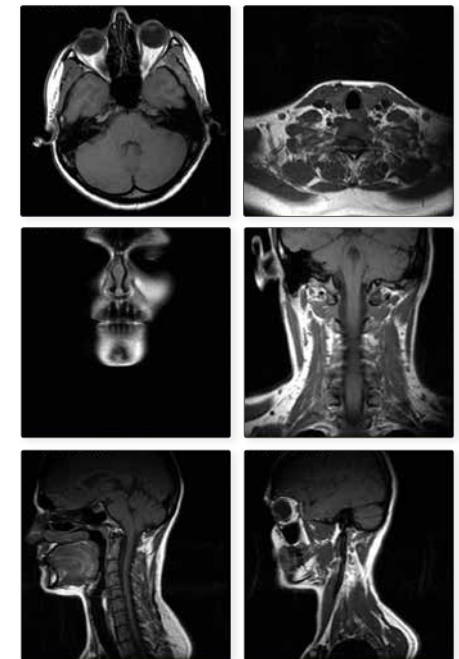
The **Clinical slides** consist of photographs, scans and diagrams of common and notable clinical conditions.



Dissection slides are fully selectable photographs taken from real-life dissections.



The **MRI slides** from the Imaging tab are collected here*, allowing you to export them for use in your own presentations, patient education, and student handouts.



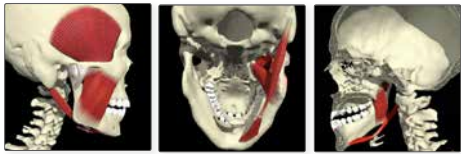* The Imaging tab in CT and MRI: Thorax, Pelvis and Abdomen does not contain MRI slides.

Main tabs – Movies



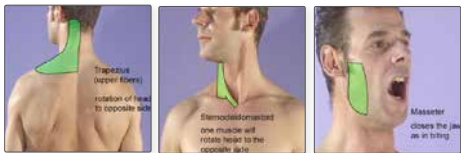The **Movies*** tab can contain movies of both the 3D model in motion and real-life movies that demonstrate anatomical concepts.

Movies of muscle movements in the 3D model



MOVIES TAB

Surface anatomy movies



Note that the movie playback controls are specific to the browser you are using.

Play/Pause

Scrub backwards and forwards

Maximize

Chrome browser on desktop only: save movie in **mp4** format. For all other browsers, use the **Save** tab to save the movie in **mpg** format.

* Movies do not feature in CT and MRI: Thorax, Pelvis and Abdomen

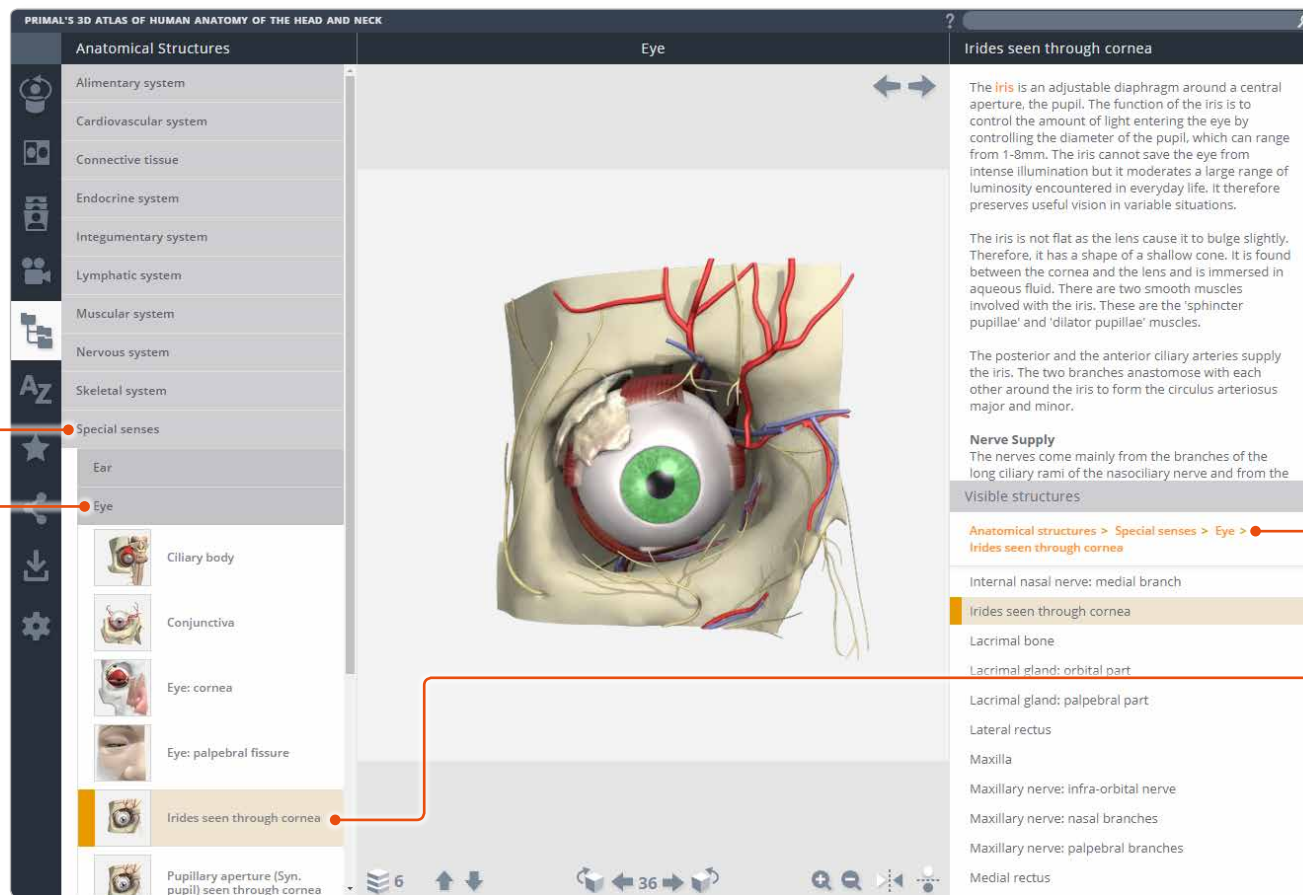
Main tabs – Anatomical structures



Use the **Anatomical structures** tab to browse through the entire contents, sorted systemically.

ANATOMICAL STRUCTURES TAB

Systemic folders and sub-folders help you to locate content and understand anatomical relationships.



Quick tip: when the Anatomical structures tab is closed, clicking on the Visible structures cookie-crum will open the Anatomical structures tab at the currently selected structure.

Main tabs – Index



Use the **Index** to find content alphabetically.

The screenshot displays the software interface for 'PRIMAL'S 3D ATLAS OF HUMAN ANATOMY OF THE HEAD AND NECK'. The 'Index' tab is active, showing an alphabetical list of folders. The 'AZ' folder is highlighted, and a red arrow points to it with the label 'INDEX TAB'. Below the index, a list of anatomical structures is shown, including 'Lacrimal apparatus', 'Lacrimal artery', and 'Lacrimal bone'. A red arrow points to the 'Lacrimal apparatus' entry with the text: 'Each entry is accompanied by an icon, indicating the content type.' To the left of the interface, a legend lists content types with corresponding icons: 3D view, MRI, Structure, Animation, Slide, Clinical, Movie, and Patient info. The main window shows a 3D anatomical model of the lacrimal apparatus with labels: 'Lacrimal gland: orbital part', 'Lacrimal gland: palpebral part', 'Lacrimal punctum', 'Lacrimal canals', 'Lacrimal sac', and 'Nasolacrimal duct'. The top of the window shows the title 'Lacrimal apparatus' and 'Labyrinthine artery (Syn. internal auditory artery)'.

If there is no content for a particular letter, the folder will be grayed-out.

Main tabs – Favorites



Save your favorite 3D views, slides, movies, animations, anatomical structures and clinical articles into your own folders.

Add favorite

Opens the **Add favorite** dialogue box, where you can specify a name and folder location for your new Favorite.

Add folder

Opens the **Add folder** dialogue box where you can specify a name and location for your new folder.

Save to file

Favorites are stored locally on your computer. If you would like to access them on another computer, you will first need to **Save to file**. This creates a .txt file which you can then transfer to the other computer.

Load from File

Use the **Load from file** button to import your previously created .txt Favorites file to the new computer.

FAVORITES TAB

Opening folders

Open folders by clicking on the arrow to their left.

Selecting a Favorite or a Favorites folder will reveal its **Edit** and **Delete** buttons.

You can relocate your Favorites and Favorites folders by dragging them from one folder to another.



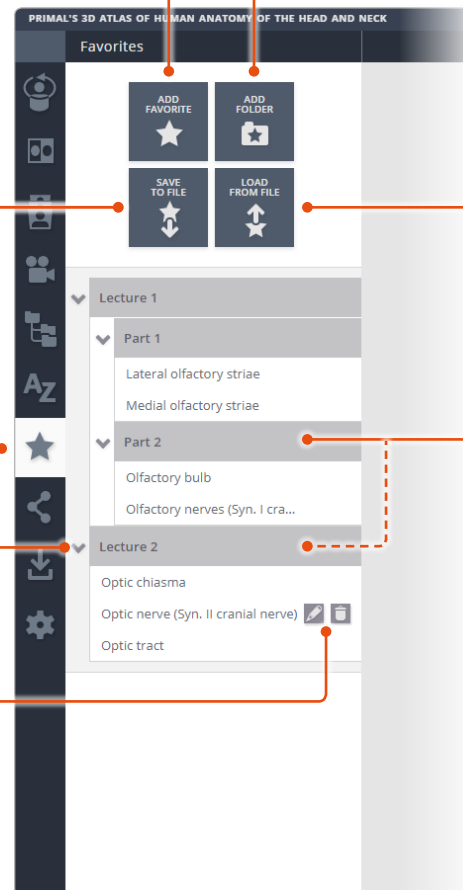
Edit

Allows you to rename a selected Favorite or folder or to specify a different folder location.



Delete

Deletes your selected Favorite or folder from the Favorites tab.



Main tabs – Share



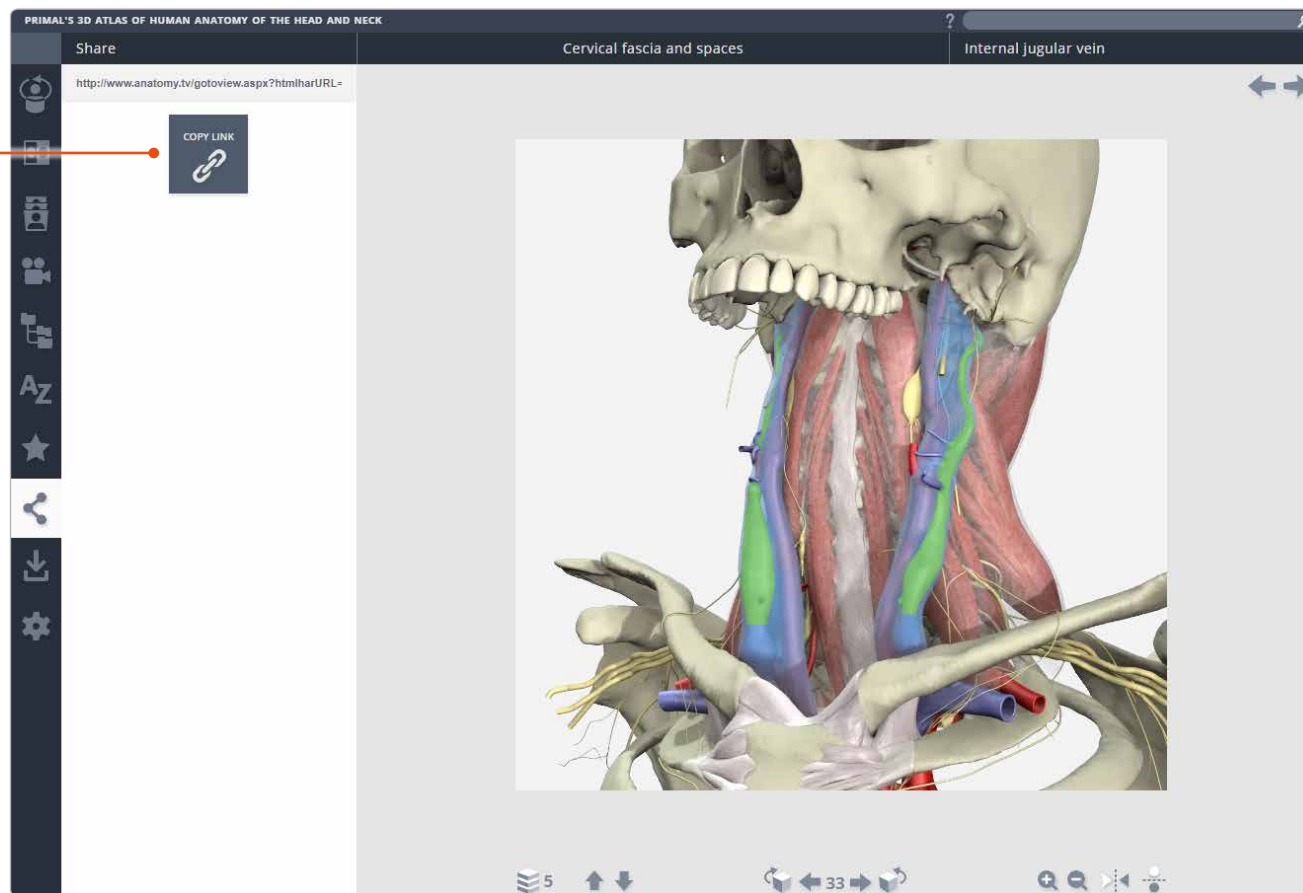
Share views with other Anatomy.tv subscribers.

Copy link

Click this button to generate a hyperlink which you can copy and email to your fellow subscriber.

Links can also be pasted into a Learning Management System to link students directly to content in the products.

SHARE TAB



Main tabs – Save



You can save images, movies and text articles, enabling you to add them to presentations, lecture notes, and Learning Management Systems.

Save image
Clicking this button will save the current 3D sequence frame, animation frame or slide, according to which type of content is currently shown in the View panel.
If you are currently viewing a Movie, the **Save movie** button will be shown instead.

SAVE TAB

Save text
Saves the text article of the currently selected structure.

PRIMAL'S 3D ATLAS OF HUMAN ANATOMY OF THE HEAD AND NECK

Save Dural folds and sinuses Cerebellum

SAVE IMAGE SAVE TEXT

The cerebellum is the second largest mass of nervous tissue of the brain and is the largest part of the hindbrain. It lies in the **posterior cranial fossa** dorsal to the pons and medulla. Its median region is separated from the pons and medulla by the fourth ventricle.

The cerebellum is roughly spherical in shape and occupies the posterior cranial fossa, covered by the tentorium cerebelli, but somewhat constricted in its median region and flattened. It is broadest transversely.

Function
The cerebellum helps to control and co-ordinate familiar movements.

7 63 Visible structures

Main tabs – Settings



The **Settings** tab has a number of controls which allow you to adjust how you view the 3D model.

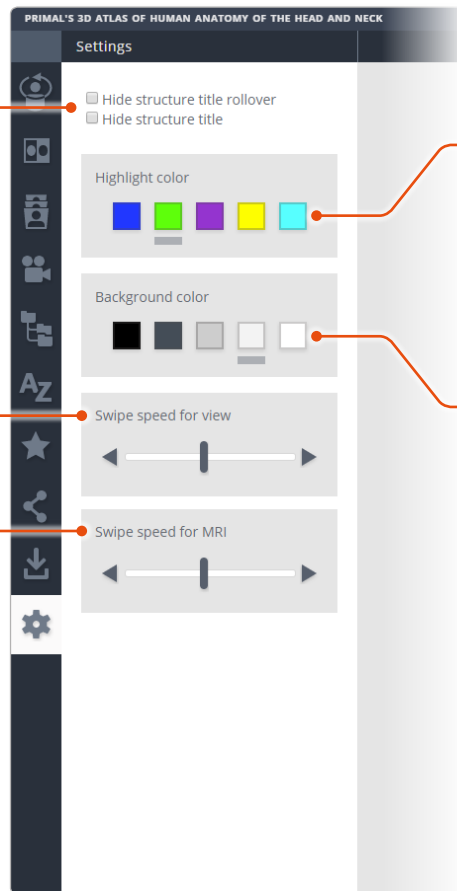
Hiding titles

Useful for self-testing, these check-boxes allow you to hide the View pane rollover labels or the titles above the View panel and Text panel.

Swipe speed

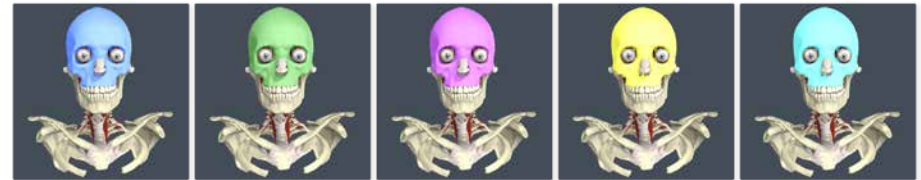Adjust how quickly you move through the frame sequence while swiping.

SETTINGS TAB



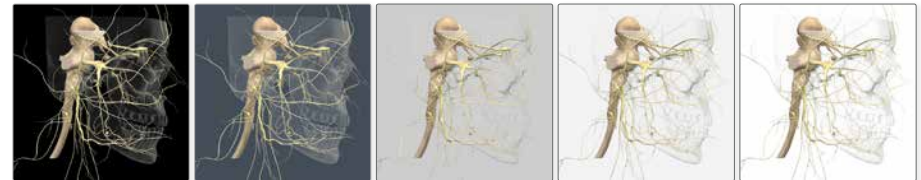
Highlight color

You can choose a different highlight color to make your selection more visible. The highlight color will also change in selectable slides.



Background color

The background color can also be adjusted to make structures more visible. (Currently only available in Chrome browser on desktop.)



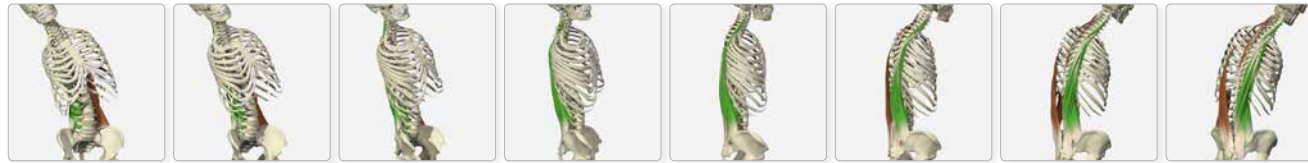
Specialist tabs – Animations



Many of our specialist titles also feature an **Animations*** tab.

Animations differ from movies in that they can be rotated and viewed from different angles.

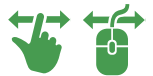Also, structures are selectable in animations.



ANIMATIONS TAB

The screenshot shows the 'FUNCTIONAL ANATOMY' application. The left sidebar has the 'Animations' tab selected. The main window displays a 3D model of the human trunk and head, with the mandible highlighted in purple. A progress indicator shows 91%. The interface includes a navigation bar at the bottom with a play button and a seek bar.

For the smoothest playback we recommend waiting for the entire sequence to load.



Drag with your finger or mouse to move forwards and backwards through the frame sequence.

You can also use the playback controls to play forwards, pause and play backwards.

Use the rotation controls to view the animation from different angles.

The play-head can also be dragged back and forth to examine the motion in more detail.

* The Animations tab is not available in 3D Atlas titles; Ultrasound titles; CT and MRI; Dentistry.

Specialist tabs – Clinical



Many of our specialist titles also include a **Clinical*** tab.

1

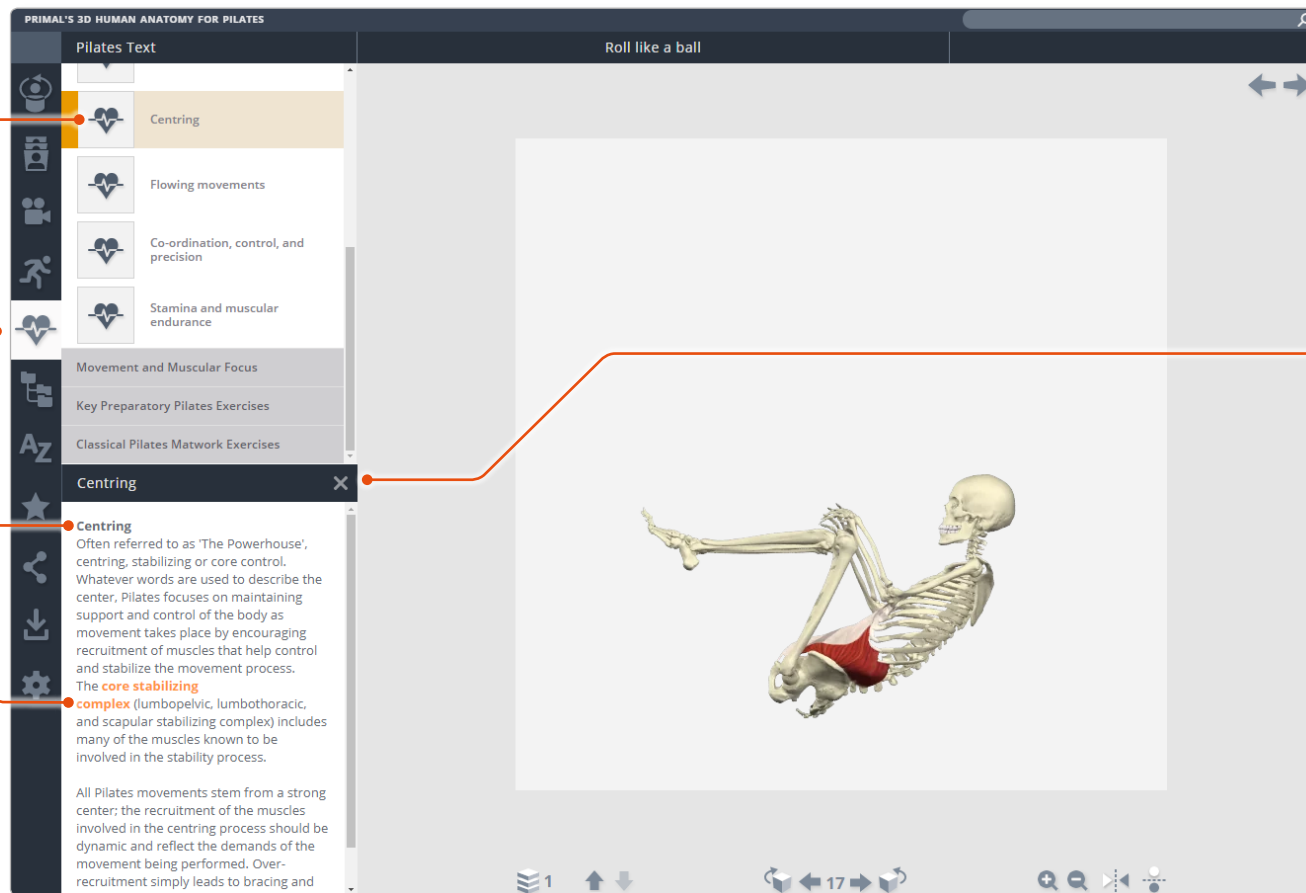
Select a clinical article from within the folder list.

CLINICAL TAB

2

The clinical article appears in a box at the bottom of the Browse panel.

Many of the articles contain links to related content.



3

The Clinical article box will remain open even when you select other tabs. Close it by clicking on the cross.

* The Clinical tab features in Exercise; Pilates; Yoga; Ultrasound titles; Otolaryngology; Chiropractic; Dentistry; Dental Hygiene; Pelvic Floor Disorders; Speech Language Pathology.

Specialist tabs – Patient information



Some of our specialist titles also include a **Patient info*** tab.

2

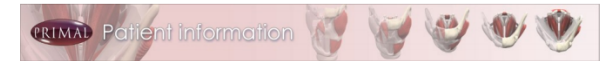
Patient information documents can be saved or printed, or added to PowerPoint presentations or Learning Management Systems.

PATIENT INFO TAB

1

Select a patient info document from within the folder list. The documents may be in PDF or Word format. Word format documents can be edited to suit your requirements.

The screenshot shows a software interface for 'SPEECH LANGUAGE PATHOLOGY'. The 'Patient Info' tab is active, displaying a list of documents under the 'Larynx' category. The documents include 'Flexible endoscopic evaluation of swallowing (FEES)' in both PDF and Word formats, and 'Modified barium swallow' in both PDF and Word formats. A 3D anatomical model of the larynx is shown in the center, with a red circle highlighting a specific area. The interface also features a sidebar with navigation icons and a bottom toolbar with various controls.



What is a Flexible Endoscopic Evaluation of Swallowing (FEES)?

A flexible endoscopic evaluation of swallowing is a procedure used by clinicians to evaluate the safety and effectiveness of swallowing.

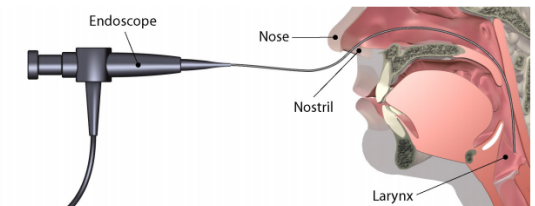
Some of the reasons to perform this examination include:

- dysphagia (difficulty swallowing)
- cough
- globus (the feeling of a lump in your throat)
- choking
- reflux (back-flow of acidic stomach fluids)
- parkinson's disease
- stroke

What Happens During a Flexible Endoscopic Evaluation of Swallowing (FEES)?

The clinician performing the examination may be a speech therapist or a physician.

You will be placed in a standard examination chair and an endoscope (a small tube with a camera) is passed through one nostril, and the structures of the pharynx (throat) and larynx (voice box) are visualized and examined.



The endoscope may be attached to a monitor and projected onto a screen and recorded for later playback and analysis. If a small puff of air is administered through the endoscope to test for sensation in the pharynx, the examination is called a flexible endoscopic evaluation of swallowing with sensory testing, or FEESST.

The information contained in this publication should not be used as a substitute for the medical care and advice given to patients. Copyright © 2010 Primal Pictures Ltd

* The Patient info tab features in Urology; Pelvic Floor Disorders; Speech Language Pathology.